

Epileptic Seizures in Patients with Multiple Sclerosis

S. Papagiannopoulos¹, M. Zampaki¹, E. Koutsouraki², D. Kazis¹, D. Vlaikidis¹, O. Argyropoulou¹, N. Vlaikidis¹

SUMMARY

Epileptic Seizures are considered a rare symptom of Multiple Sclerosis and may appear as the first and only clinical manifestation of the disease.

Of the 330 patients (107 males and 223 females) that were seen over the past seven years in one clinic, 11 (five males and six females) suffered from at least one epileptic seizure. Men (4.67%) were more likely to experience seizures than women (2.69%).

Focal seizures were more frequent, occurring in eight out of 11 cases (72.7%). Patients with multiple sclerosis proved to be much more sensitive than non-MS- patients with regard to side effects when administered older antiepileptic drugs, while in three patients (27.3%) the seizures ceased after the anti-inflammatory treatment with Methylprednisolone, without the use of anti-epileptic medicine becoming necessary.

INTRODUCTION

Multiple Sclerosis (MS) is a chronic neurological disease, which can cause almost any neurological symptom. Epileptic seizures are considered to be a rare symptom of MS and may appear as the first and only clinical manifestation of the disease¹ or simultaneously with other neurological and psychiatric symptom² during its course, both at the onset of a relapse as well as in the intervals between relapses.

When seizures represent the initial manifestation of the disease, MS often remains undiagnosed for a long period of time, and thus mean the condition is not optimally treated or managed.

Although there is no consensus among researchers regarding the incidence of epileptic seizures in MS, it is generally accepted that in MS patients it lies at between two to three times higher than in controls³. The exact causal mechanism of seizures in MS patients remains unknown, yet is believed to be associated with inflammation, edema, or demyelination both within the cortex as well as the sub-cortical white matter.

METHODOLOGY

The study was performed at the 3rd Neurological Clinic of Aristotle University of Thessaloniki, at the "G. Papanicolaou" Hospital. Within the seven-year period, of the 330 patients monitored, 11 experienced at least one seizure.

The diagnosis of MS was based on the McDonald criteria^{4,5} and the diagnosis of seizures was based on the patients' anamnesis and case history (not only in its original form but also in its updated form, with additional information obtained after the initiation of the study, both from themselves as well as third party reports from their environment), and electroencephalographic testing according to the International League Against Epilepsy guidelines (International League Against Epilepsy: ILAE^{6, 7}).

The aim of the study was to determine the frequency and clinical characteristics of seizures in patients with MS and to correlate seizures and other clinical findings with magnetic resonance imaging (MRI) and electroencephalographic (EEG) findings, as well as to correlate the time of manifestation of seizures with that of the onset of MS.

DATA

This section holds the case notes for the 11 patients presenting seizures.

Case 1

¹ 3rd Clinic of Neurology of the Aristotle University Thessaloniki

² 1st Clinic of Neurology of the Aristotle University Thessaloniki

Female, manifested at age 11 peripheral facial nerve palsy, followed by multiple episodes of multifocal numbness, gait instability, drops, and tremor of the upper extremities. After the five initial relapses, neurological symptoms subsided completely (initially spontaneously and subsequently after administration of methylprednisolone). Brain MRI revealed multiple minor lesions in the periventricular white matter and two in the arbor vitae.

Six years after the manifestation of MS, at the age of 17, at the onset of a relapse, she manifested generalized tonic-clonic epileptic seizures, diplopia, and urinary incontinence.

The EEG displayed slow temporal theta and delta activity with at times differing laterality predominance.

The Brain MRI at age 17 showed an increase in the number of periventricular white matter lesions bilaterally, as well as new subcortical lesions mainly on the left hemisphere as well as in the arbor vitae around the fourth ventricle.

Although no antiepileptic treatment was initiated, the patient remained free of seizures and MS relapses for the next two years, yet later resumed manifesting Grand mal seizures every 2 to 3 months, whereupon she was put under treatment with sodium valproate (500 mg 1x3), which was discontinued 2 years later due to hair loss.

Carbamazepine was then administered, which led to orthostatic hypotension and a decrease in the number of white blood cells and was subsequently discontinued. Oxcarbazepine and vigabatrin therapy followed. In the last seven years solely Levetiracetam treatment (initially 1500 and subsequently 1000 mg) has been administered leading to complete seizure control.

At the age of 20, the patient transitioned to secondary progressive MS with slow progressive worsening of gait and cognitive functions.

Brain MRI revealed widespread demyelination in the periventricular white matter bilaterally, subcortically mainly in the left hemisphere, as well as in the cerebellum.

Methylprednisolone, azathioprine and later interferon B1b every 2 days s.c. were administered. Due to continued deterioration (EDSS: 6), the patient underwent autologous transplantation of mesenchymal stem cells in an attempt to inhibit MS deterioration, whereupon stabilisation of her condition was achieved.

Case 2

Male, 17 years old with numbness and weakness in right upper limb (writing difficulty) as first event symptoms. The symptoms subsided completely after administration of methylprednisolone. After 1.5 years development of diplopia and ever since, up to the age of 40, he has developed diverse neurological symptoms every 1 to 2 years in combination with severe fatigue. All symptoms subsided completely after methylprednisolone. Brain MRI showed multiple lesions in the white matter bilaterally, mainly periventricularly.

At age 40, MS progression to secondary progressive form with predominant clinical manifestations of left lower limb weakness and gait difficulty, with persistent worsening of symptoms.

Patient received γ -globuline 0.4 g / kg every 3 weeks, Azathioprine 50 mg 1x3 for a short period of time, and FK-506 (Tacrolimus, immunosuppressant) in the United States without improvement.

At the age of 42 he presented with focal epileptic seizures beginning from the lower right extremity with secondary generalization. Oxcarbazepine 300mg 1x3 was initially and Gabapentin 600mg 1x2 supplementally prescribed, thus achieving total seizure control.

Two years later, and with new successive relapses treated with Methylprednisolone which led to relative transient improvement, however a clear decline in cognitive functions was observed.

In an attempt to inhibit continued deterioration (EDSS: 5), the patient underwent autologous transplantation of mesenchymal stem cells. The patient then had no recurrence of relapse for seven years.

For the last 8 years the patient has been experiencing relapses every two years (always in September (!)), mainly presenting with paraparesis and balance disorder, which are being treated with methylprednisolone.

MRI of the brain showed multiple bilateral white matter lesions of the hemispheres, mainly periventricularly, at the genu of the corpus callosum, the inner capsule on the right, the subcortical white matter, the frontal lobe on the left, as well as the pons. Still, there was no note of enlargement of ventricular or subarachnoid space.

EEG was abnormal due to the presence of intermittent slow polymorphic activity bilaterally frontally (more prominently on the left than on the right) as well as temporally on the left.

Case 3

Male, 43-years-old presented with a sudden generalized tonic-clonic epileptic seizure.

The Brain computer tomography (CT) findings cited a "space-occupying cystic process with perifocal oedema parietally in the right hemisphere with peripheral invasion with peripheral right peripheral edema and with peripheral contrast agent enhancement", as is usually the case with glioblastoma, metastasis or abscess, as well as a subcortically situated "lesser lesion".

Brain MRI then showed multiple lesions of the semi-oval centres periventricularly and frontoparietally subcortically, as well as of the brain stem and the inferior cerebellar peduncles. The largest of which was situated frontoparietally on the left where (like in the CT) it was bordered by cerebral edema and was enhanced circularly with contrast agent (Image 1). There was no cerebral atrophy present.

The EEG recorded theta and delta sharp and slow waves frontoparietally on the right. Neurological clinical examination revealed marked pyramidal tract syndrome to the left.

Magnetic Resonance Spectroscopy (MRS) as well as CSF screening for malignant cells and oligoclonal IgG fractions, and CSF culture (for the possibility of brain abscess) were performed. A stereotactic biopsy was also performed. The findings of the above diagnostic tests led to the diagnosis of Multiple Sclerosis.

The seizures were initially controlled through treatment with Phenytoin 100 mg 1x3, which however was discontinued due to a sharp increase in hepatic enzymes, a decrease in white blood cells and severe gait instability. Levetiracetam 1000 mg 1x3 was then administered maintaining complete seizure control. Interferon B1b s.c. every two days was chosen for immunomodulatory treatment.

For 4 years, the patient remained seizure free and presented no changes in his clinical findings. Rest-EEG rest was definitely abnormal due to the persistent presence of slow polymorphic theta and delta waves temporoparietally on the right as well as rare spikes and sharp waves of same localisation.

After two years, the patient presented with renewed epileptic seizures, mental disorder (Organic Manic Depressive Psychosis) and a decline in cognitive functions. As the patient had no familial support, he no longer followed treatment plans and died at age 48 due to a suspected cardiac arrest.

Case 4

Male MS patient since age 18. The disease manifested with speech disorder, muscle weakness, and fine motor skill deficit of the right upper limb.

After 3 months MS relapse with right upper limb muscle weakness with frequent (up to 10 daily) focal seizures, which extended ipsilaterally from the upper right to the lower right limb and the ipsilateral half of the neck.

The EEG recorded left frontal spikes and bilateral slow waves.

Carbamazepine 400 mg 1x2 was administered, and was discontinued after one month as the seizures had subsided.

After 2 months renewed relapse with speech disorder, muscle weakness and impaired fine motor skill of the right upper limb.

MRI of the brain revealed multiple small periventricular lesions in the semioval centers of the cerebrum as well as subcortically. The local neurologist prescribed Interferon B1a 22 mg s.c. thrice weekly.

Brain MRI 2 years after the onset of the disease showed demyelinating lesions of the white matter in the semioval centers, periventricularly, in the posterior limb of the internal capsule bilaterally, as well as the cerebral peduncles, none of which showed enhancement after i.v. administration of MRI contrast agent.

Three years after the onset of the disease, the patient discontinued immunomodulatory treatment and remained symptom-free for 8 years.

He recently suffered a relapse with right upper and lower extremity numbness, disruption of the right upper limb fine motor skills, abduction paresis, and resting tremor. Interferon B1b every two days was prescribed.

In the latest brain MRI, compared to an MRI performed 9 years ago, there was a slight size increase in one of the left sided periventricular lesions, as well as a newer lesion dorsal to it, without pathological contrast enhancement.

Rest EEG (including hyperventilation) during his last hospitalization was without pathological findings.

Case 5

A 48-year-old male presented with the rare ataxia-dysarthria disorder, which is considered a "canalopathy" usually on a substrate of demyelinating disease. Bilateral pyramidal tract and cerebellar syndromes could be objectively identified.

Brain MRI showed the expected damage to the midline of the brainstem, ventrally to the aqueduct, abdominal aorta, as well as smaller lesions to the white matter of the frontal lobes bilaterally.

Carbamazepine XR 200mg x3 was administered, leading to a remission of the clinical symptoms.

The patient relapsed after three months with left-sided retrobulbar neuritis, right pyramidal tract syndrome as well as bilateral thermohypesthesia up to/at a Th12 level.

An additional 1g of Methylprednisolone was administered for 5 days followed by tapering, again resulting in a full remission of symptoms. Interferon B1b s.c. prescription every 2 days followed.

After 45 days there was a new relapse. The patient complained of very easy development of fatigue. Bilateral pyramidal tract syndrome and decoloration of the lateral half of the optic disc on the left as well as excessive sentimentality were observed. Carbamazepine and Interferon B1b treatment continued.

After 5 months another relapse with right-sided retrobulbar neuritis and right pyramidal tract syndrome. Interferon was replaced with Fingolimod.

The patient showed remarkable improvement, but later, about six months after the administration of Fingolimod, a new relapse with ataxia, dysarthria, severe difficulty in gait up to gait failure and high fever with increased lymphocyte count.

Brain MRI revealed numerous lesions of varying size. The largest were located at the base of the frontal lobe on the left, on the right cerebellopontine angle and the brainstem. Lesions were also observed in the subcortical white matter bilaterally and the corpus callosum. Of all the lesions, contrast agent enhancement was present in the one in the brainstem and the right cerebellopontine angle (the latter in the form of Balo concentric sclerosis).

All of the above findings are consistent with tumefactive demyelinating lesions.

Despite the intravenous administration of methylprednisolone the patient deteriorated and presented focal seizures of the upper and lower limbs on the right, and in the following days, severe respiratory failure, whereupon he was intubated and admitted to the ICU, where he was subjected to plasmapheresis and after to administration of γ -globulin.

A new brain MRI showed enlargement of the lesions with severe edema and midline structure shift.

Rest EEG showed slow waves, mainly theta, bilaterally and without predominance of one side. The patient eventually died at the age of 49.

Case 6

Female, 15 years old, experienced focal sensory and motor seizures, starting from the left upper extremity with secondary generalization to tonic convulsions and loss of consciousness, which were treated with Oxcarbazepine 300mg x2 daily.

Brain MRI revealed demyelinating lesions periventricularly and slight enlargement of the temporal horn of the right lateral ventricle (hippocampal gliosis).

The EEG between attacks, recorded slow theta left temporal activity. EEGs performed one and two years later recorded brain activity within normal limits.

A few months after the last EEG a blurriness of vision of the left eye and diplopia occur. After paraclinical and laboratory testing, left retrobulbar neuritis in MS was diagnosed.

In the new brain MRI, following the episode of retrobulbar neuritis, relatively larger demyelinating lesions were found, which were not enhanced by contrasting agent, mainly around the ventricles and the semioval centers.

The new EEG recorded activity within normal limits.

Six months after the episode of retrobulbar neuritis there was a relapse with right hemiparesis.

The newest brain MRI also showed new lesions in the periventricular and subcortical white matter and the corpus callosum. Two of them (one parietal and one temporal in the left hemisphere) were enhanced with contrast agent.

The subsequent EEG recorded brain activity within normal limits.

One year later (without relapse of MS, no further seizures and continuing treatment with Oxcarbazepine at the same dosage) the EEG was mildly pathological due to the presence of infrequent slow polymorphic theta activity in the occipital and parietal left hemisphere. However, no epileptiform activity was recorded.

Case 7

Female, 19 years old, with diplopia in all directions except to the right and spinning vertigo.

MS was diagnosed after paraclinical and laboratory testing. Treatment with intravenous administration of methylprednisolone led to a rapid normalization of the clinical picture.

MRI of the brain revealed multiple lesions with abnormal signal intensity in the subcortical parietal white matter bilaterally, as well as a more sizable lesion frontally right, measuring 1,58 x 1,10 cm with central gliosis (Image 2). Another relatively sizable lesion was located in the right hemisphere of the cerebellum. Another area with abnormal signal intensity adjacent to the occipital horn of the right lateral ventricle showed enhancement after intravenous administration of contrast agent.

Two months later, the patient developed a level of consciousness disorder, during which she did not respond to visual or auditory stimuli yet responded to painful stimuli. To examine the possibility of clinically silent epileptic seizures an EEG was performed, which recorded generalized discharges in the form of spike and sharp-wave activities, with a clear right sided predominance. No antiepileptic treatment was required.

Case 8

Female, 16 years old, with blurriness of vision episode of the left eye and orbital pain during eye movements for four days due to left-sided retrobulbar neuritis. After 4 months persisting diplopia when looking to the right. Complete retreat of symptoms after intravenous administration of Methylprednisolone 500 mg daily for five days.

4 years later relapse with right hemiparesis, balance disorder with left-sided fell and bilateral cerebellar syndrome, more pronounced on the left.

The MRI revealed numerous lesions in the white matter of the cerebral hemispheres and in the arbor vitae bilaterally. Interferon B-1b 256 µg s.c. every 2 days was prescribed, with excellent improvement.

The patient, already being a fourth-year medical student independently replaced interferon B-1b with interferon B-1a 30 µg i.m. once weekly after four years. A relapse followed three months later with both bilateral pyramidal tract (more pronounced on the right) as well as cerebellar syndrome (more pronounced on the left), head tremor and diplopia in all eye movement directions.

Following administration of methylprednisolone, a colleague of hers replaced interferon B-1a i.m. once weekly with B-1a (44 µg) s.c. thrice weekly. The patient presented multiple new relapses that were treated with Methylprednisolone in the city where she had established herself as a physician.

The patient continued to have relapses with bilateral pyramidal tract and cerebellar syndrome symptomatology, head tremor, as well as focal sensory and motor epileptic seizures in combination with dysesthesia, that began from the right half of the neck and radiated to the ipsilateral shoulder, upper arm and the right half of the face and that were treated with Gabapentin 600mg x3 daily.

During a hospital stay, 15 years after the onset of the disease, multiple demyelinating white matter lesions were found on the brain MRI, which showed no contrast agent enhancement. There was also an enlargement of the ventricular system and the subarachnoid space as well as thinning of the corpus callosum in the context of cerebral atrophy.

The EEG recorded scattered slow theta waves and intermittent polymorphic slow activity in the left frontoparietal region.

A treatment with Natalizumab 300 mg every four weeks i.v. was administered, with excellent clinical improvement.

Case 9

A 36-year-old woman with vertiginous attacks and gait disorder due to inability to properly steer her lower limbs.

Brain MRI showed multiple periventricular demyelinating lesions on the white matter. The patient was put on treatment with interferon B-1a 30 µg i.m. once weekly, which, due to intolerance, was replaced after three months with interferon B1a (44 µg) s.c. thrice weekly.

After 6 months vesicorectal disorders manifested and after 2 years the patient developed recurrent relapses and focal Jackson seizures, which extended ipsilaterally from the left upper limb to the lower limb. Symptoms subsided completely after administration of 1g Methylprednisolone i.v. for five days. No anti-epileptic treatment was required.

At the same time, however, an increase in disability was also observed.

During her hospitalization in our clinic, the Brain MRI revealed multiple lesions in the periventricular white matter of the cerebral hemispheres, as well as in the brainstem, without enhancement. Slight enlargement of the ventricular system was also shown.

The MRI of the cervical spine revealed additional lesions in the C4 - C6 segment of the spinal cord and the patient was treated with Natalizumab 300 mg i.v. every four weeks, which was discontinued after 3 years, due to high JC antibody titers and risk of progressive multifocal leukoencephalopathy, and replaced with fingolimod treatment.

Case 10

Male, 24 years old, mechanical engineer, with weakness and hypesthesia of the lower limbs and torso up to the navel. MRI revealed multiple demyelinating lesions in the periventricular white matter of the cerebral hemispheres, as well as in the cervical spinal cord.

After two months additional development of diplopia, dysarthria and ageusia.

In the neurological examination bilateral pyramidal tract syndrome with cloni, bilateral cerebellar lower extremity tremor and anisocoria with a wider left pupil which nevertheless responds well to both light and accommodation. Symptoms subsided completely after administration of 1g Methylprednisolone i.v. for five days.

Relapse after a month, again with weakness and hypesthesia of the lower limbs and trunk up to the navel, diplopia, dysarthria and ageusia.

Complete remission of symptoms after administration of 1g Methylprednisolone i.v. for five days. He was then treated with Interferon B1b s.c. every second day.

Relapse after eight years with left sided abduction paresis, dysarthria, bilateral pyramidal tract and cerebellar syndrome, combined with panic attacks, more severe in the evening.

The patient became antisocial, avoided strangers, and shut himself in his room. "When visitors come home, I feel them breathing my air." Complete remission of symptoms again with 1g Methylprednisolone i.v. for five days and Fluoxetine 20mg daily. The immunomodulatory treatment was also changed to Interferon B1a 44 µg s.c. three times weekly.

After three years manifested focal Jackson seizures of the right lower limb.

The EEG records polymorphic sharp and slow waves frontoparietal. Levetiracetam 1g x2 is added leading to complete seizure control and no adverse cognitive effects.

The MRI revealed a slight increase of demyelinating lesions in both the brain and spinal cord. Ever since, the disease relapses every summer, also increasing cerebral and spinal demyelinating lesion damage.

Administration of Alemtuzumab 12 mg i.v. daily for 5 days in the first year and 12 mg daily for 3 days in the second year stopped the relapses and disease deterioration while providing excellent clinical improvement.

Case 11

Female, aged 23 years, with episodes of diplopia and partial full body numbness of the left side. Since a year before, Jackson seizures of the right lower limb for a half to one minute every two to three days. Only once coinciding seizures of the right upper limb for about one minute.

During her treatment in the clinic, the EEG did not record any abnormalities. There was complete remission of symptoms after administration of 1g Methylprednisolone i.v. for five days and she was put on immunomodulatory treatment with Interferon B1b s.c. every other day. No antiepileptic treatment was required.

MRI of the brain showed a cystic formation, without abnormal contrast agent enhancement, of approximately 7 mm in diameter adjacent to and in contact with the left temporal horn (Image 3). Synthesis of pathological oligoclonal IgG bands was also detected in the CSF. She was put on immunomodulatory treatment with Interferon B1b s.c. every second day.

RESULTS

Out of the 330 patients (107 men and 223 women) who were followed for a period of seven years at the 3rd Neurological Clinic of Aristotle University of Thessaloniki, at the "G. Papanicolaou" Hospital, 11 (five men and six women) reported at least one epileptic seizure.

In 2 patients, seizures comprised the initial manifestation of multiple sclerosis, in 3 they occurred within the first six months, in 2 between six and 12 months and in 4 between six and 25 years after the onset of the disease.

Impairment of cognitive functions were noticed in 3 cases (2, 9 and 27 years after the onset of MS) and Psychiatric disturbances (Mania in one and Depression in one) in 2. Enlargement of subdural space or of the ventricular system was noticed in only one case of them.

Pathological EEG findings were recorded in 10 patients: in 5 spikes together with θ and δ slow waves and in the other 5 θ and δ slow waves without spikes.

There was total compatibility between:

Clinical presentation of ES and MRI findings in 10 cases.

Clinical presentation of ES and EEG findings in 8 cases and MRI findings and EEG findings in 10 out of 11 cases.

Incompatibility between the clinical presentation of ES and EEG findings and MRI was found only in 1 case.

Also was noticed a relationship between the occurrence of ES and the onset or recurrence of multiple sclerosis (8 in 11 cases: 72.72%).

3 patients did not require antiepileptic treatment. In 10 out of the other 11 cases, seizures subsided without any particular difficulty.

Both the older as well as the newer antiepileptic drugs were effective, however the older drugs induced significant side effects in patients with multiple sclerosis.

DISCUSSION-CONCLUSIONS

Seizures occur in 5-10% of patients with MS during the course of the disease⁸, most often after the passing of a few years with the disease remaining active⁹.

The incidence of seizures in MS patients is 2 to 3 times higher than in the general population of corresponding age, whereas the prevalence of epileptic seizures in MS patients is 3.1%³. Inflammation, degeneration and edema are considered predisposing factors for the manifestation of epileptic seizures on the grounds of cortical hyperexcitability³.

Increased neuronal excitability (cellular depolarisation due to membrane permeability disorder through immunological processes) is also implicated in inducing seizures¹⁰.

This almost same prevalence rate was established in the present study (3,33%), however of special note being that men suffered significantly more frequently (4.67%) than women (2.69%).

According to the literature, the majority of seizures are simple partial, complex partial, or secondary generalized^{3,11}.

In fact, the study also confirmed the partial seizures as being the most frequent in 8 out of 11 cases (72.7%). We note however that patients with multiple sclerosis were much more susceptible to side effects when administered older anti-epileptic drugs, and that in 3 patients (27.3%) the seizures subsided after anti-inflammatory methylprednisolone treatment without need for anti-epileptic drug treatment.

BIBLIOGRAPHY

1. Thompson AJ, Kermod AG, Moseley IF, MacManus DG, McDonald WI. Seizures due to multiple sclerosis: seven patients with MRI correlations. *J Neurol Neurosurg Psychiatry*. 1993 Dec;56(12):1317-20.
2. Laura C. Politte, Jeff C. Huffman, Theodore A. Stern. Neuropsychiatric Manifestations of Multiple Sclerosis. *Prim Care Companion J Clin Psychiatry*. 2008; 10(4): 318–324.
3. Kelley BJ1, Rodriguez M. Seizures in patients with multiple sclerosis: epidemiology, pathophysiology and management. *CNS Drugs*. 2009 Oct;23(10):805-15.
4. McDonald W, Compston A, Edan G et al. Recommended diagnostic criteria for multiple sclerosis: guidelines from the international panel on the diagnosis of MS. *Annals of Neurology*. 2001;50:121–7
5. Polman CH, Reingold SC, Banwell B et-al. Diagnostic criteria for multiple sclerosis: 2010 revisions to the McDonald criteria. *Ann. Neurol*. 2011;69 (2): 292-302
6. Seino M. Classification criteria of epileptic seizures and syndromes. *Epilepsy Res*. 2006 Aug; 70 Suppl 1:S27-33. Epub 2006 Jul 7.
7. Panayiotopoulos CP. The new ILAE report on terminology and concepts for organization of epileptic seizures: a clinician's critical view and contribution. *Epilepsia*. 2011 Dec; 52(12):2155-60. Epub 2011 Oct 17.
8. Trouillas P, Courjon J: Epilepsy with multiple sclerosis. *Epilepsia* 13:325, 1972
9. Cendrowski W, Majkowski J: Epilepsy in multiple sclerosis. *J Neurol Sci* 17:389, 1982
10. Jeffrey L. Sponsler, Anastasia C. Kendrick-Adey, seizures as a manifestation of multiple sclerosis. *Epilept Disord* 2011; 13(4): 401-10
11. Striano p, Orefice G, Brescia Morra V, Boccella P, Sarappa C, Lanzillo R, Vacca G, Striano s, Epileptic seizures in multiple sclerosis: clinical and EEG correlations, *Neurol Sci*. 2003 Dec; 24(5): 322-8

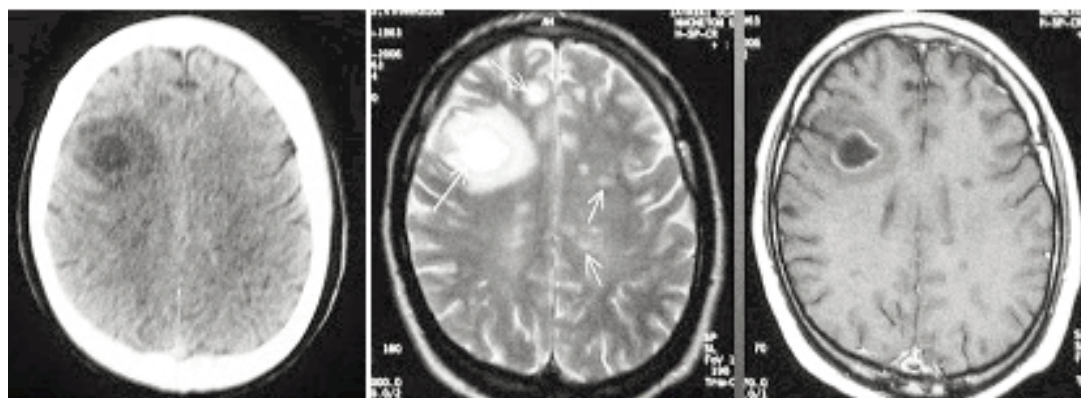


Image 1 (Case 3). T₁- and T₂-weighted scans as well as T₁-weighted scan after paramagnetic contrast medium (respectively).

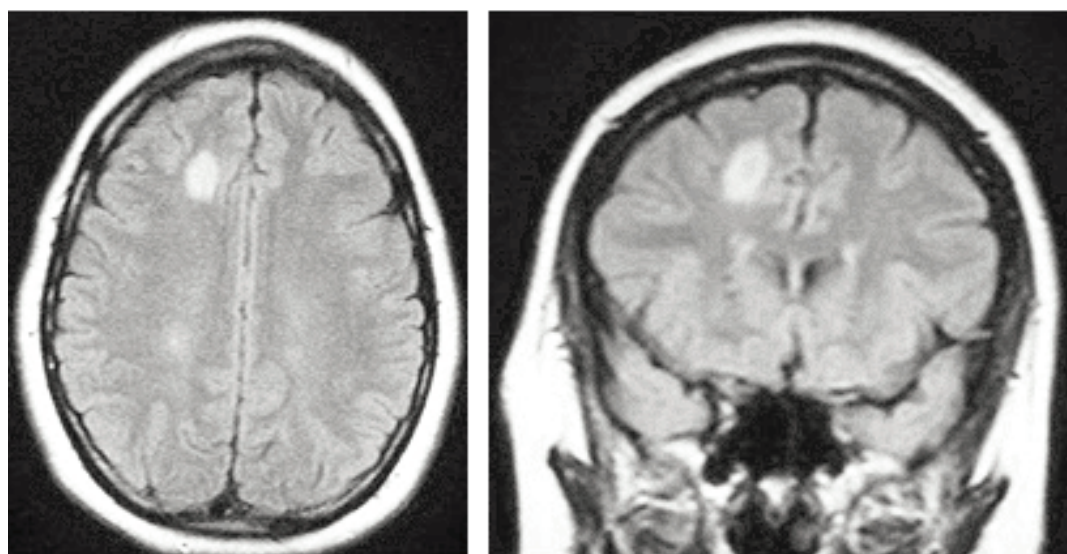


Image 2 (Case 7). FLAIR-sequence in transverse and coronal section (respectively).

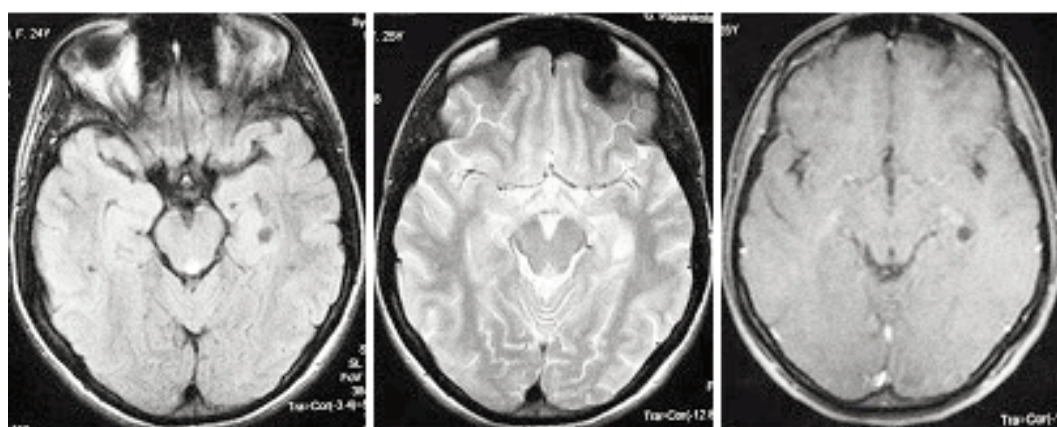


Image 3 (Case 11). T₁- and T₂-weighted scans as well as T₁-weighted scan after paramagnetic contrast medium (respectively).